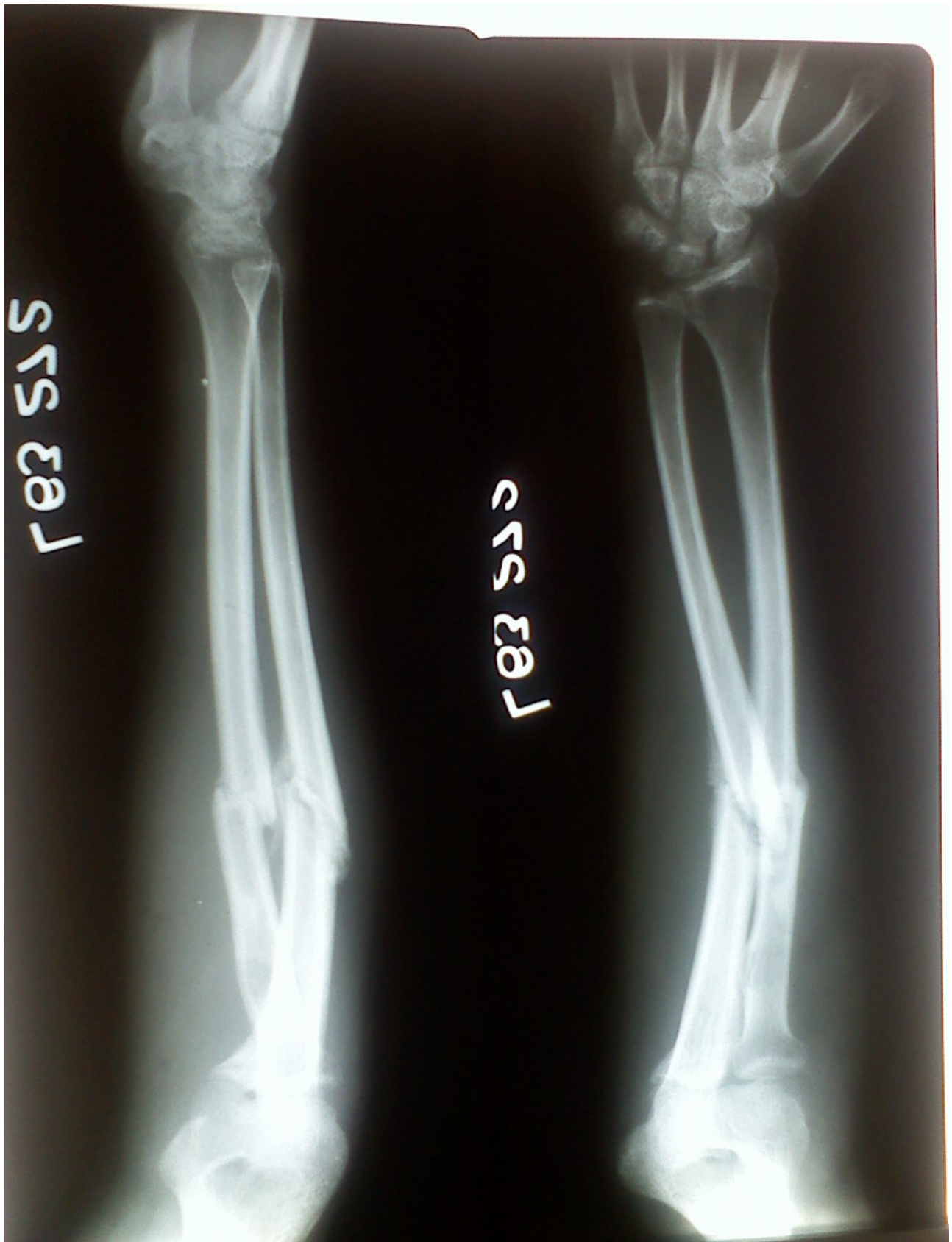


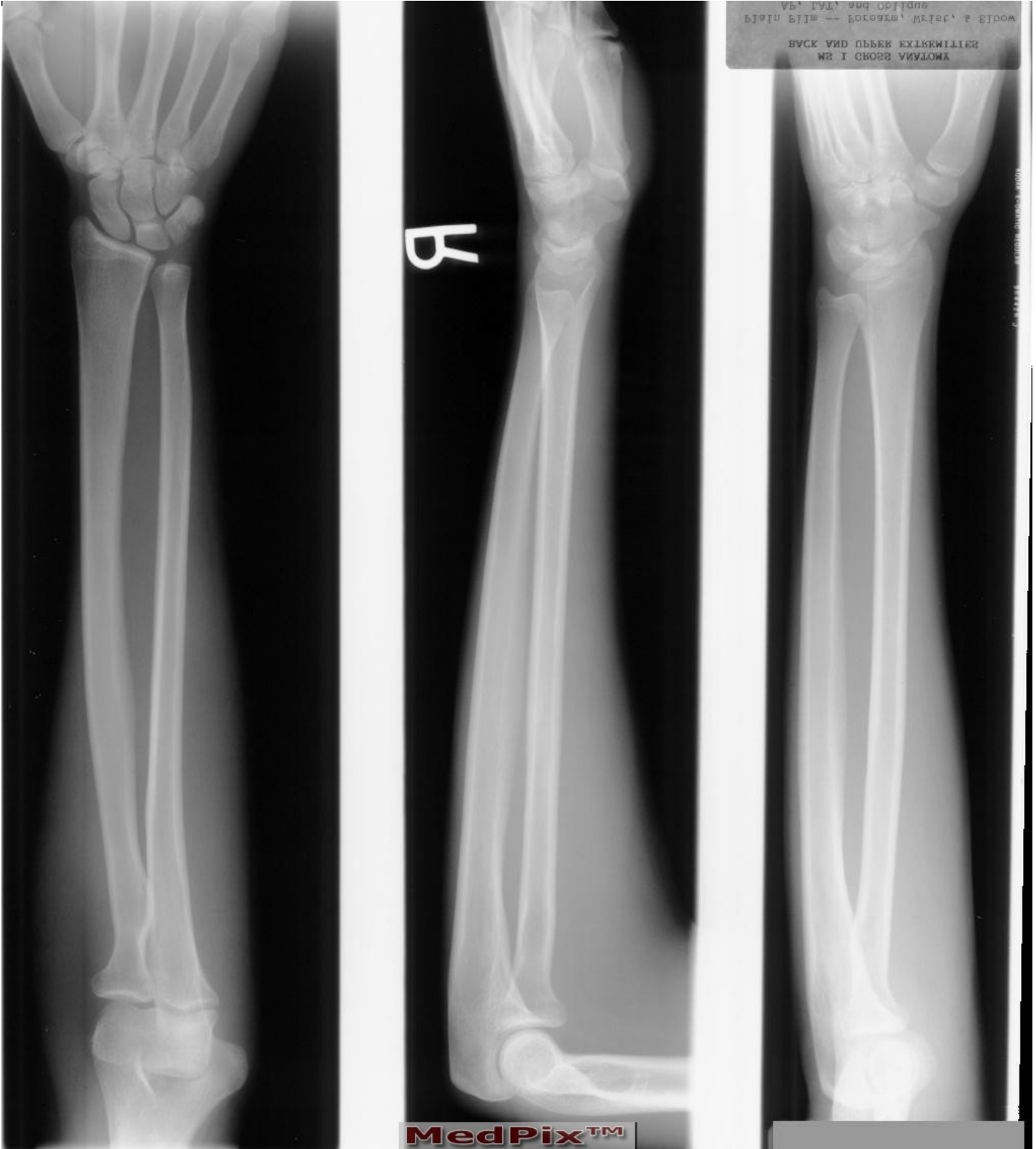Patient 1

24 y/o male experiencing forearm pain after a skateboarding fall



http://2.bp.blogspot.com/_Jw1LQHbym9w/TAiNAZdmZUI/AAAAAAAAAfM/xgteDaXPcMU/s1600/122409113206.jpg

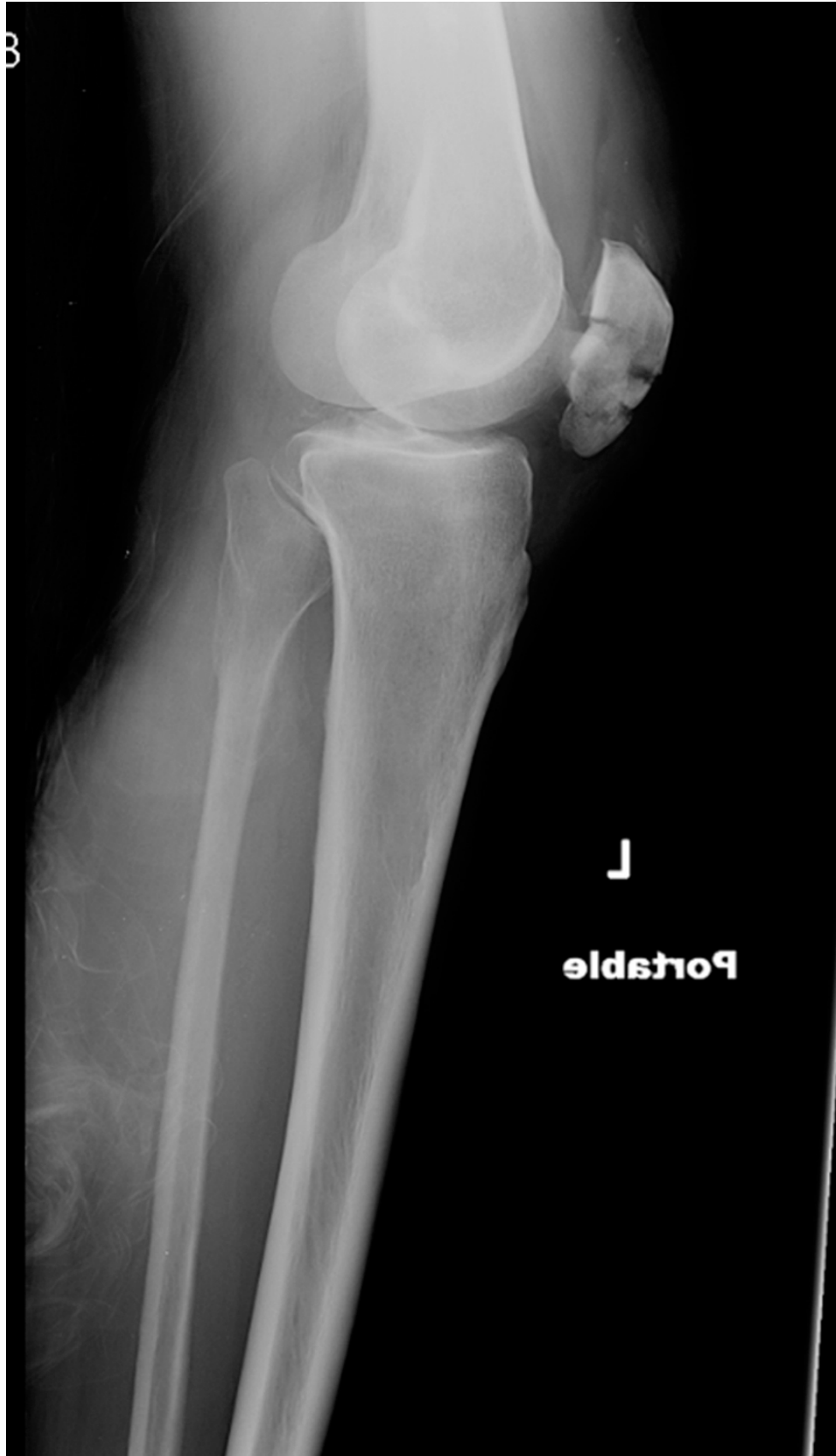NORMAL Forearm



http://rad.usuhs.edu/medpix/include/medpix_image.php3?imageid=6096

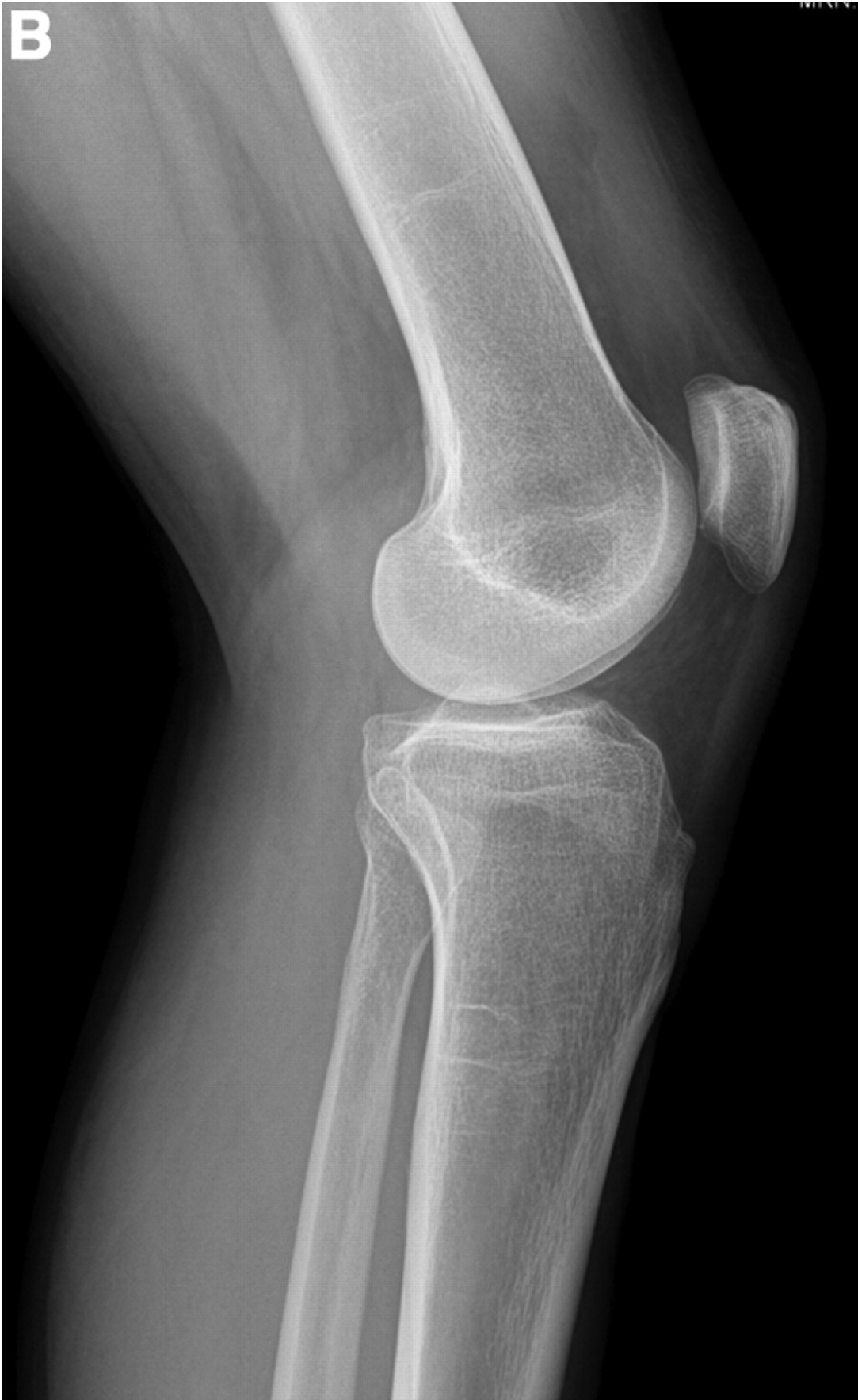Patient 2

38 y/o male experiencing knee pain after slipping on ice and hitting his knee on a rock



http://caseconnector.jbjs.org/data/Journals/JBJS/1913/CC_01_01_00048fig2.jpg

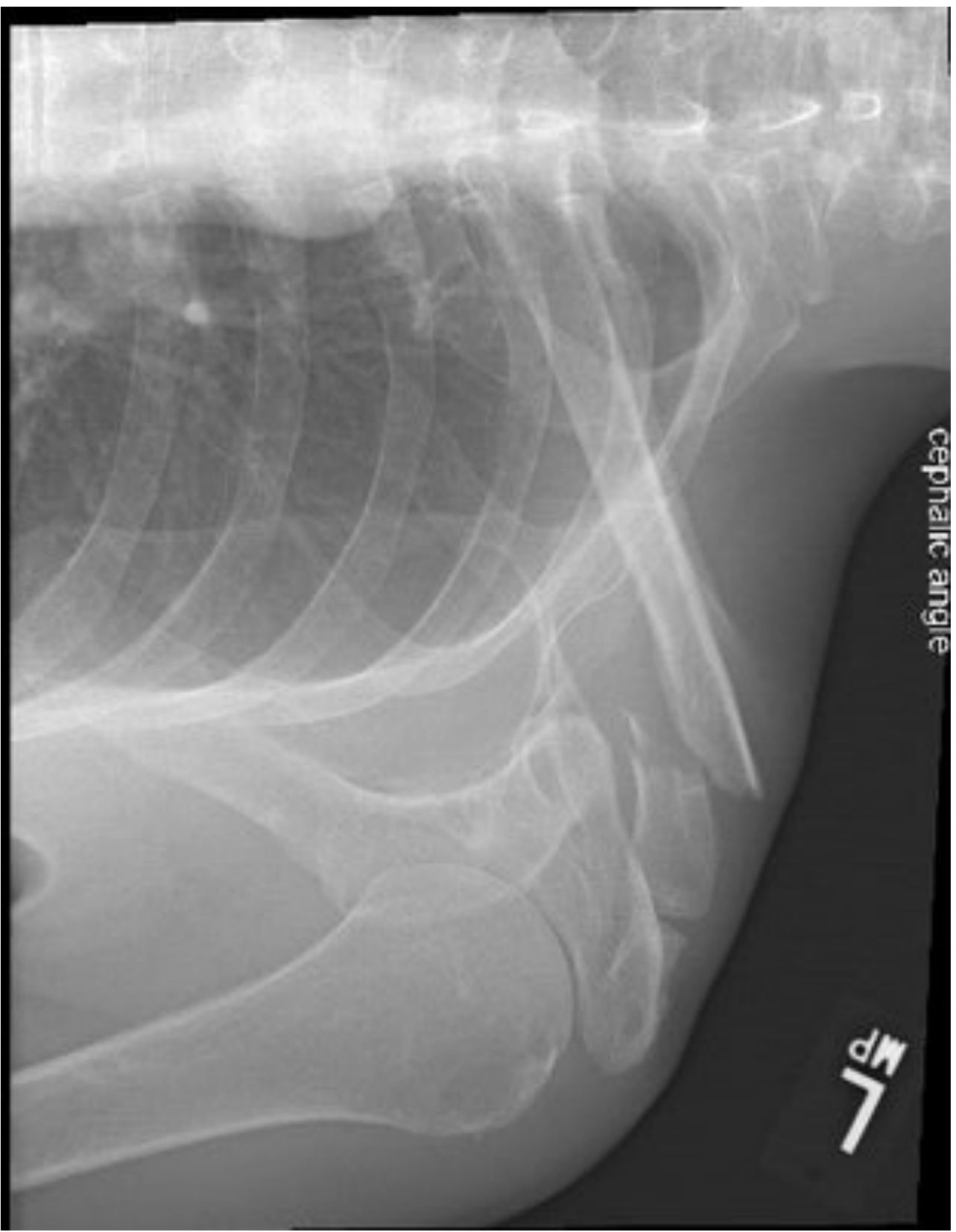
NORMAL Knee



<http://sph.sagepub.com/content/1/5/435/F1/graphic-2.large.jpg>

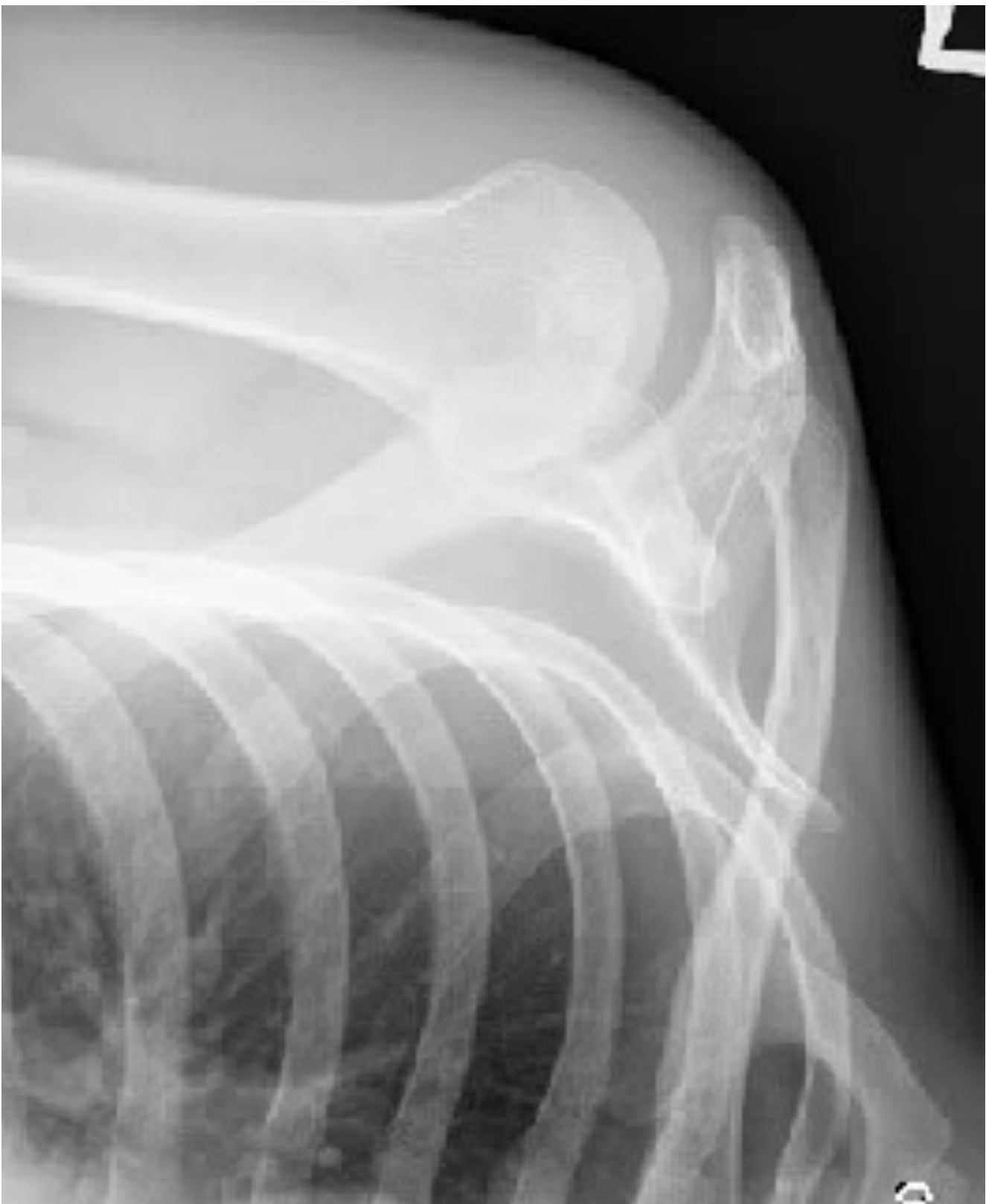Patient 3

52 y/o female experiencing severe shoulder pain after being slammed into the sand by a wave while learning how to boogie board on vacation.



http://1.bp.blogspot.com/_VuWB2k7zrIU/Sf-PQZOS1nI/AAAAAAAAAA9s/0Dj2K276ZCc/s400/Before.jpg

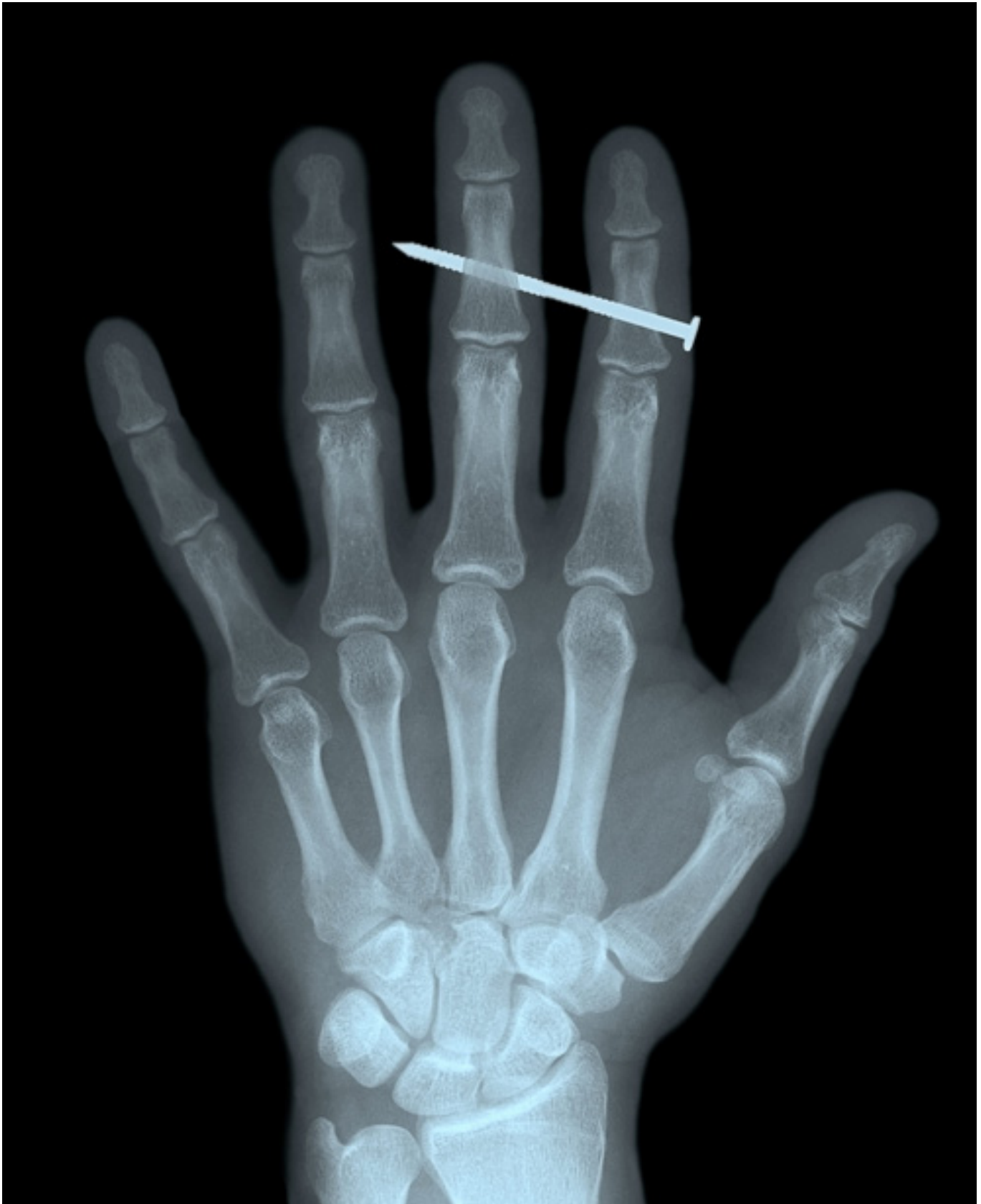NORMAL Shoulder



http://www.childrenscolorado.org/imgs/Housecalls/xray_shoulders_normal1.jpg

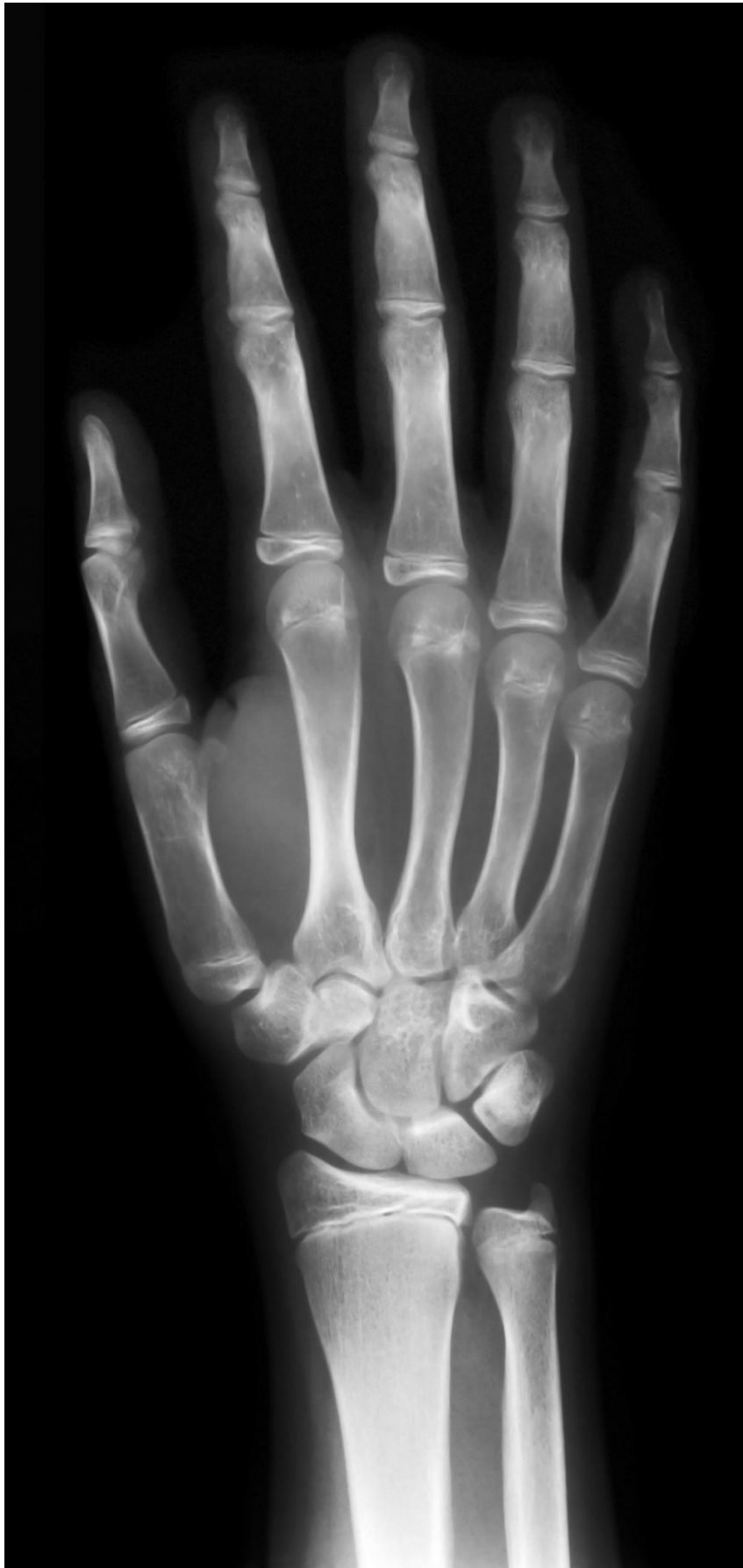Patient 4

15 y/o male experiencing hand pain after playing with a nail gun in his garage



<http://cdn.oddstuffmagazine.com/wp-content/uploads/2011/09/X-rays-2.png>

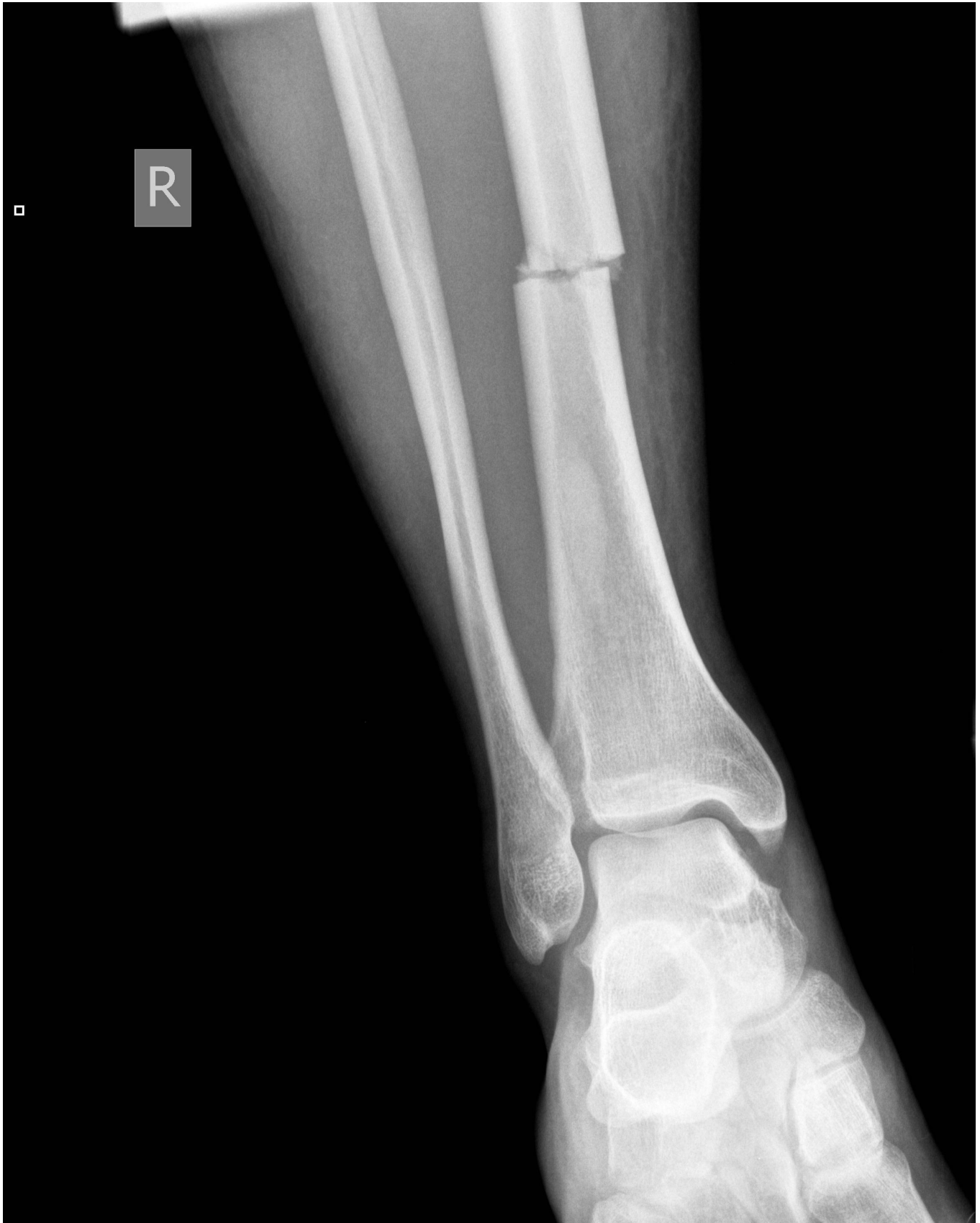NORMAL Hand



<http://images.wisegeek.com/hand-x-ray.jpg>

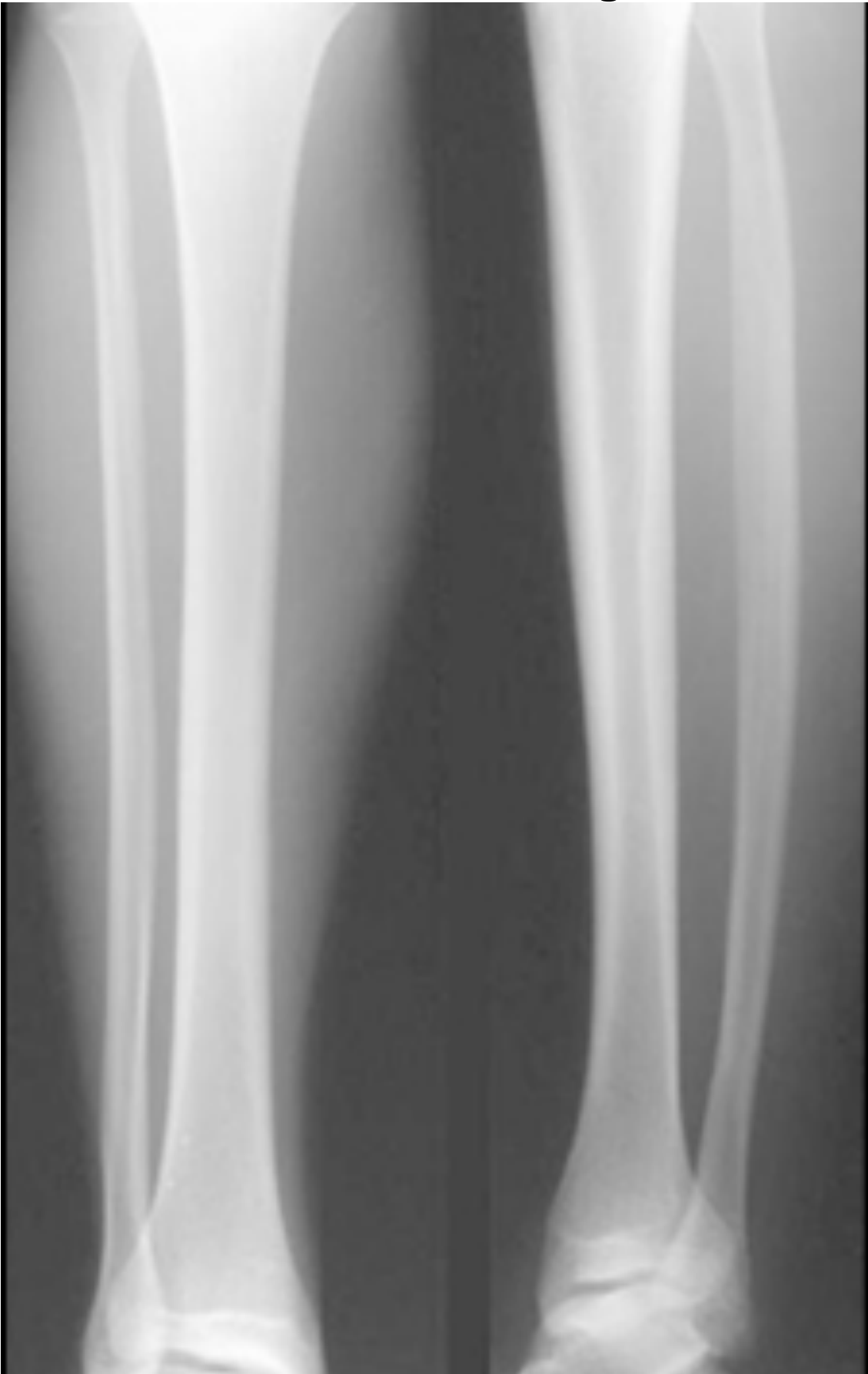Patient 5

16 y/o female experiencing shin pain after getting kicked directly in the shin during soccer practice



<http://images.radiopaedia.org/images/25340/bda64c7cbb2df2a212785f2df62550.jpg>

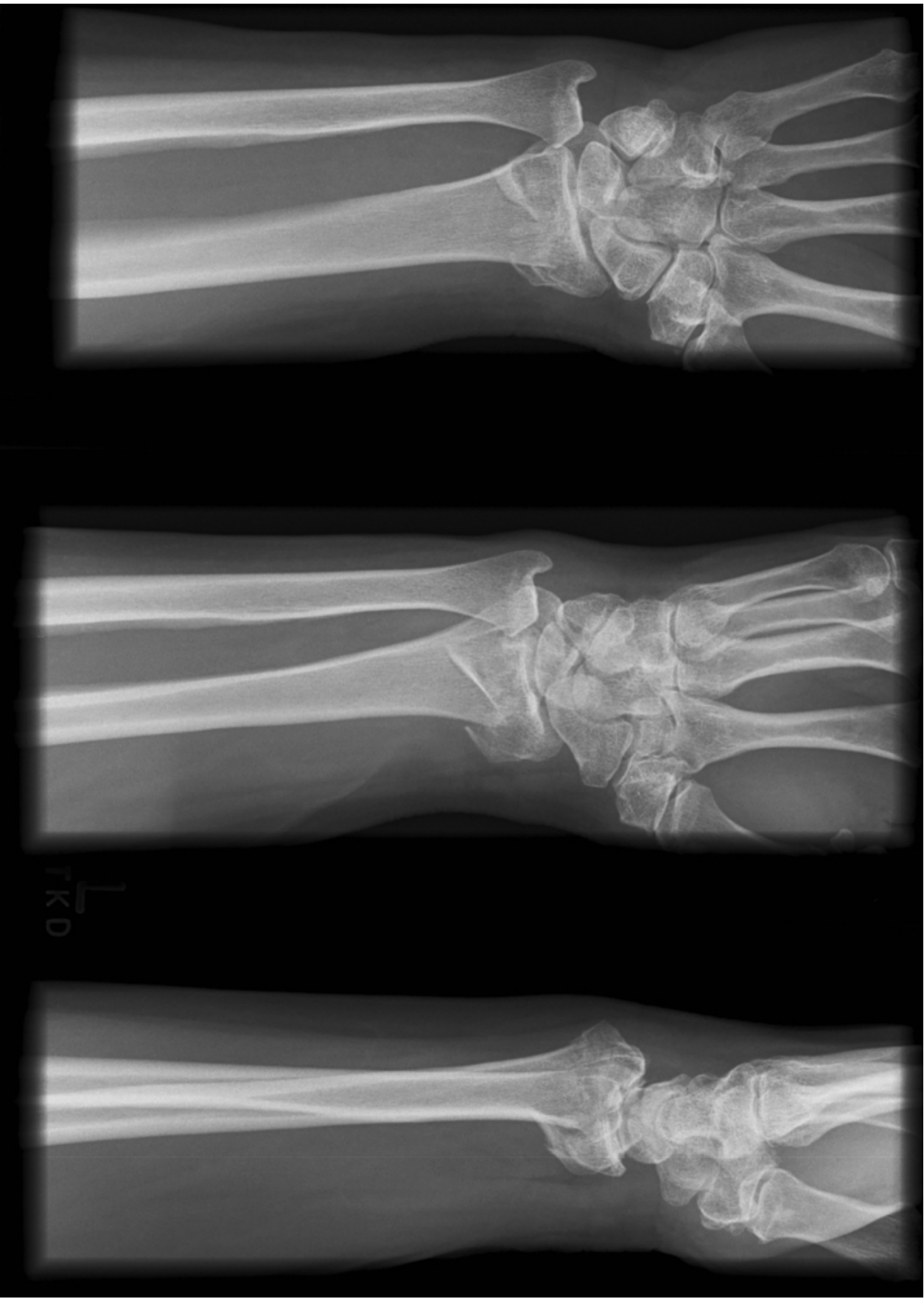NORMAL Lower Leg



<http://img.medscape.com/pi/features/slideshow-slide/overuse-injuries/fig12.jpg>

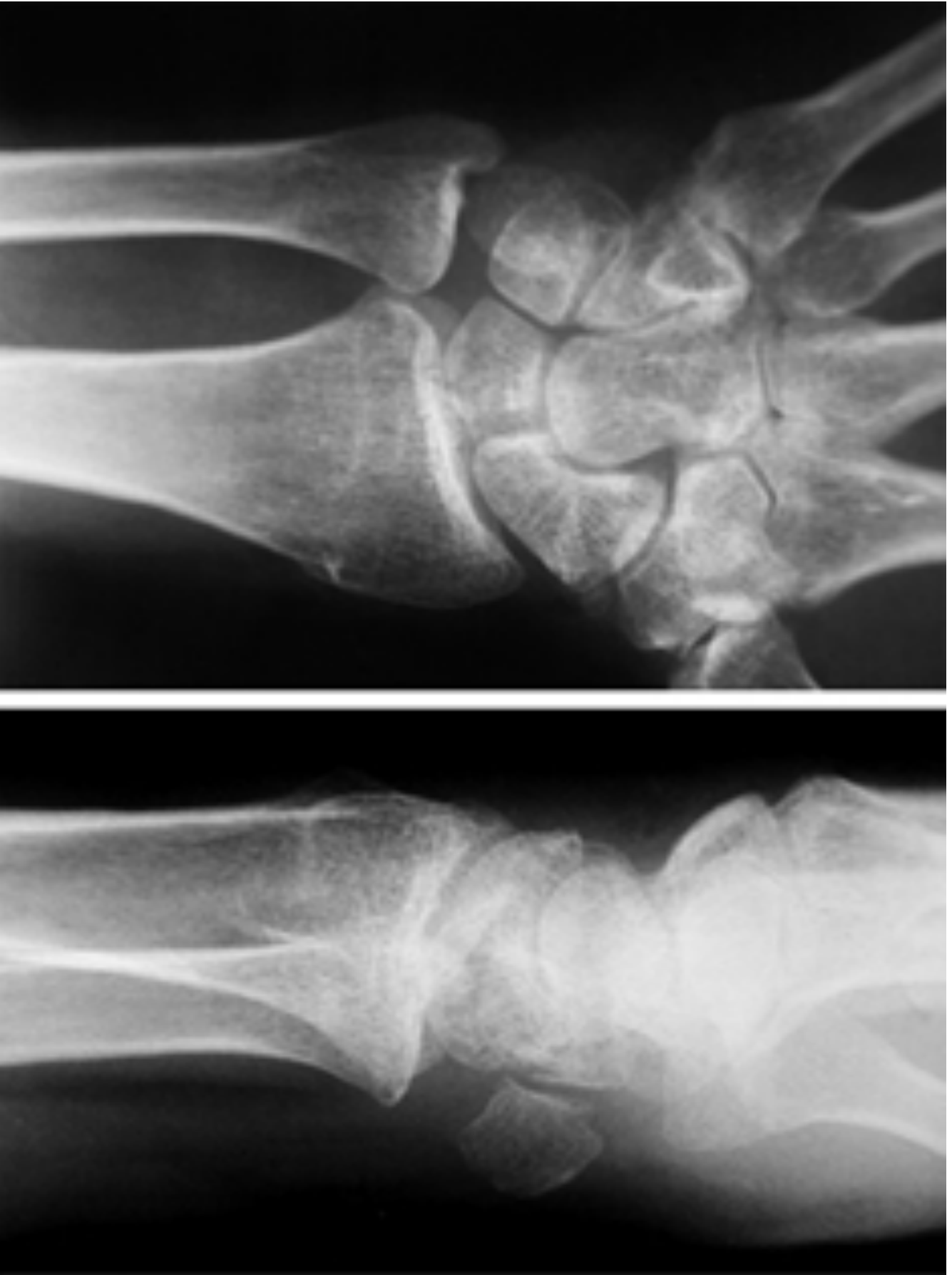Patient 6

23 y/o female experiencing wrist pain after falling while skiing.



<http://lifeinthefastlane.com/wp-content/uploads/2010/07/volar-barton-3-in-1.jpg>

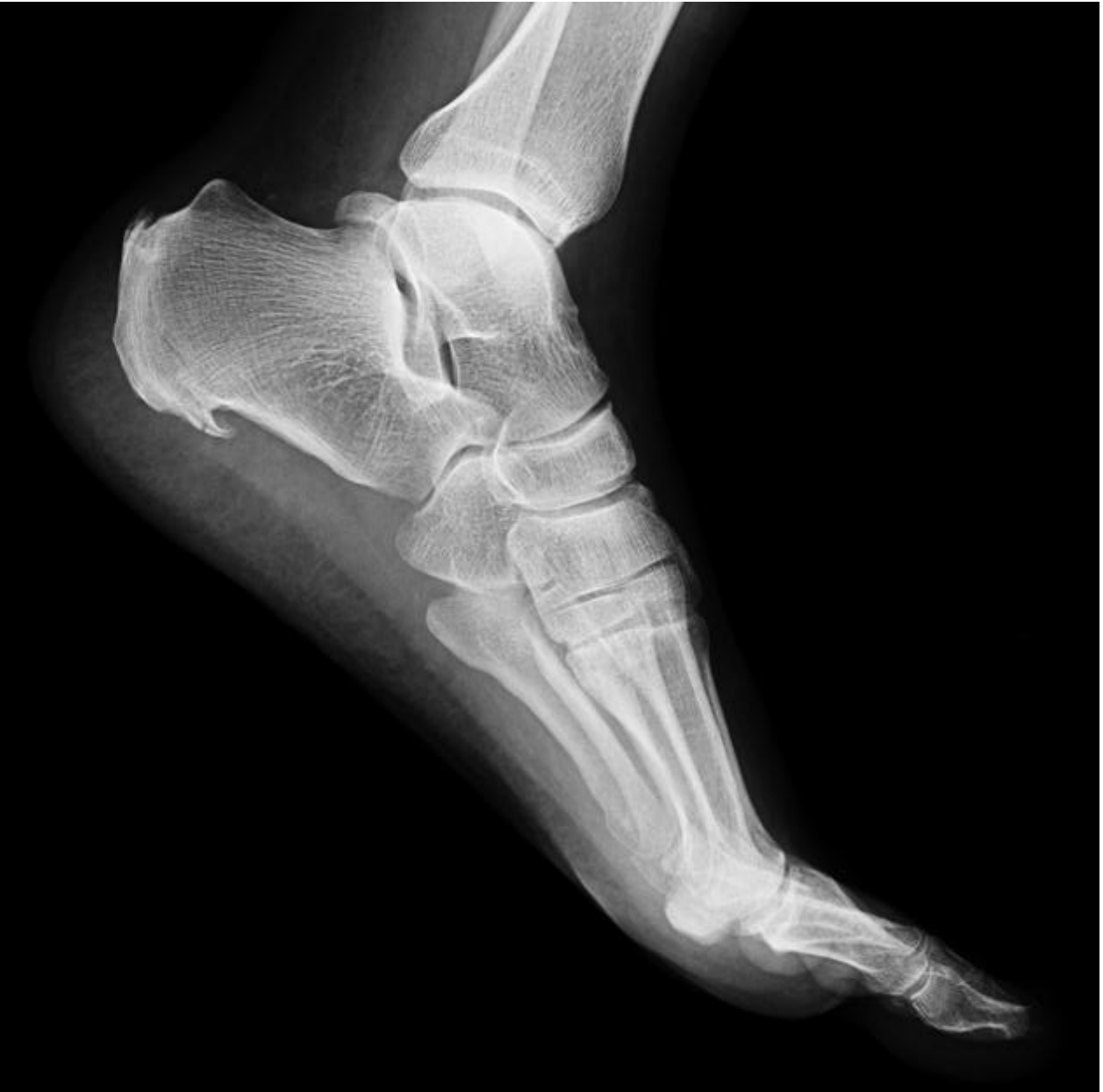NORMAL WRIST



http://nemsi.uchc.edu/images/image_distal2.jpg

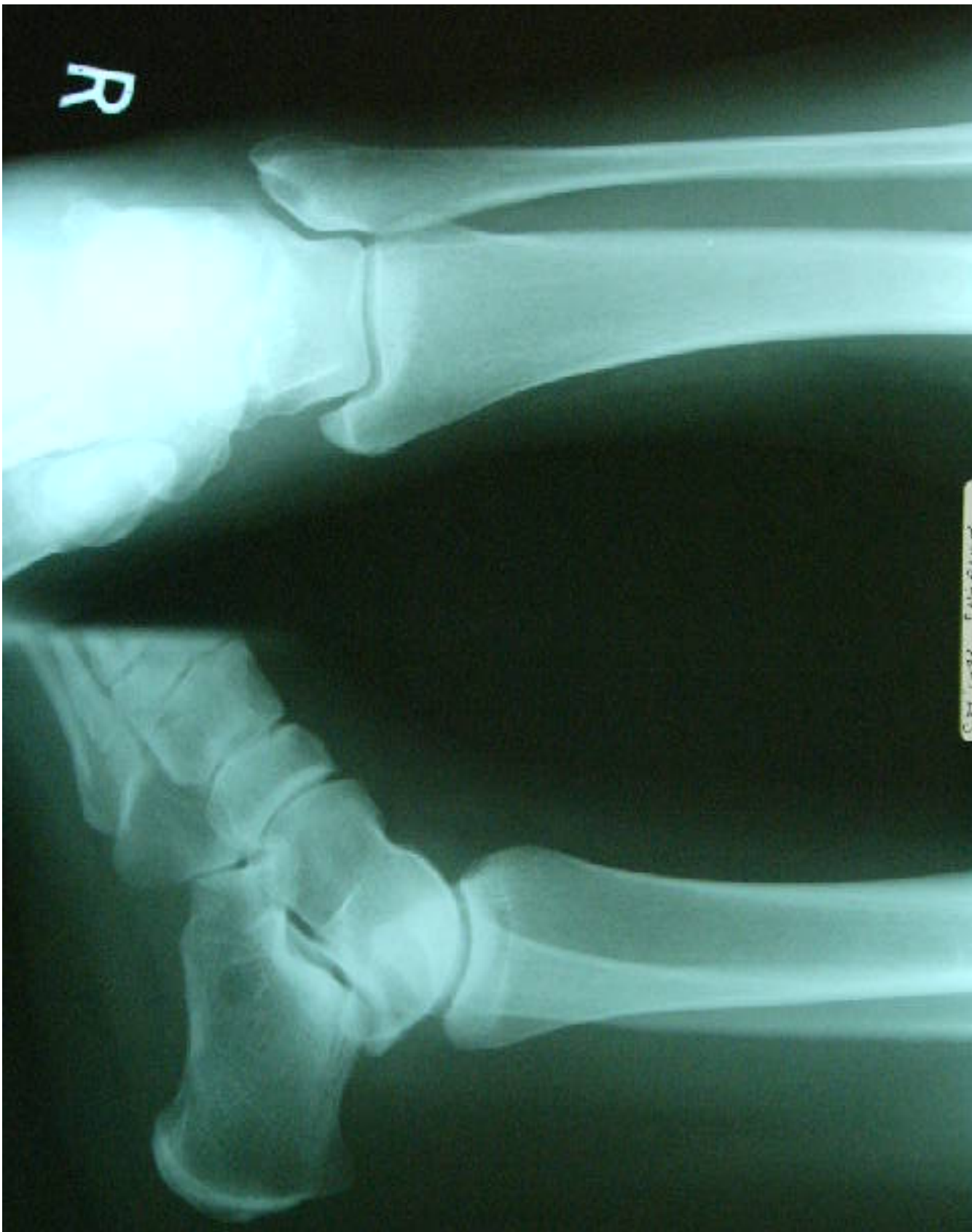Patient 7

64 y/o female who has been experiencing an increasing amount of pain in the calcaneal region over the last few months.



http://images.radiopaedia.org/images/266499/7e78b4347f53078e3724796dd0581b_big_gallery.jpg

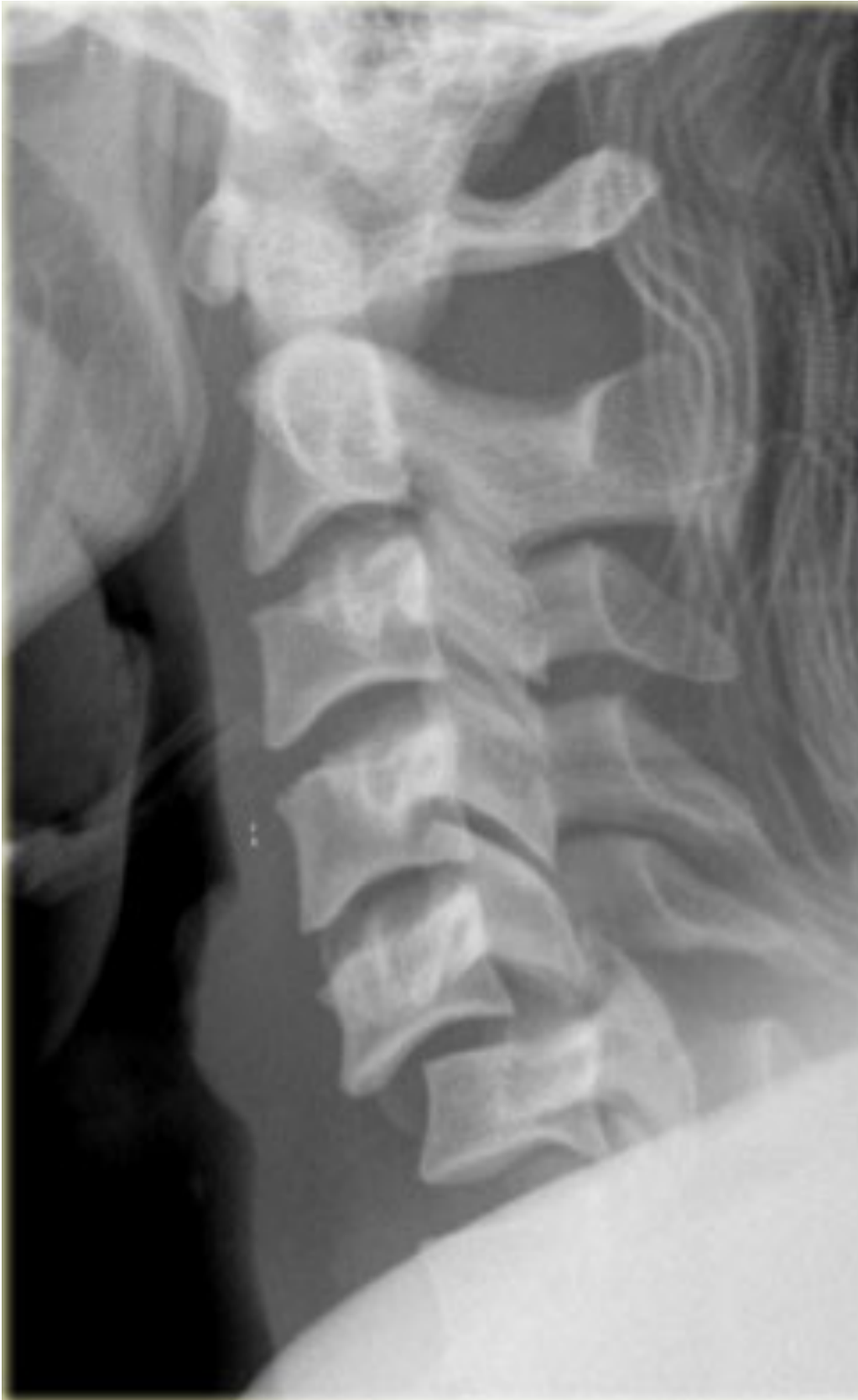NORMAL Foot/Ankle



<http://zadeuk.files.wordpress.com/2012/01/x-ray-normal-ankle.jpg>

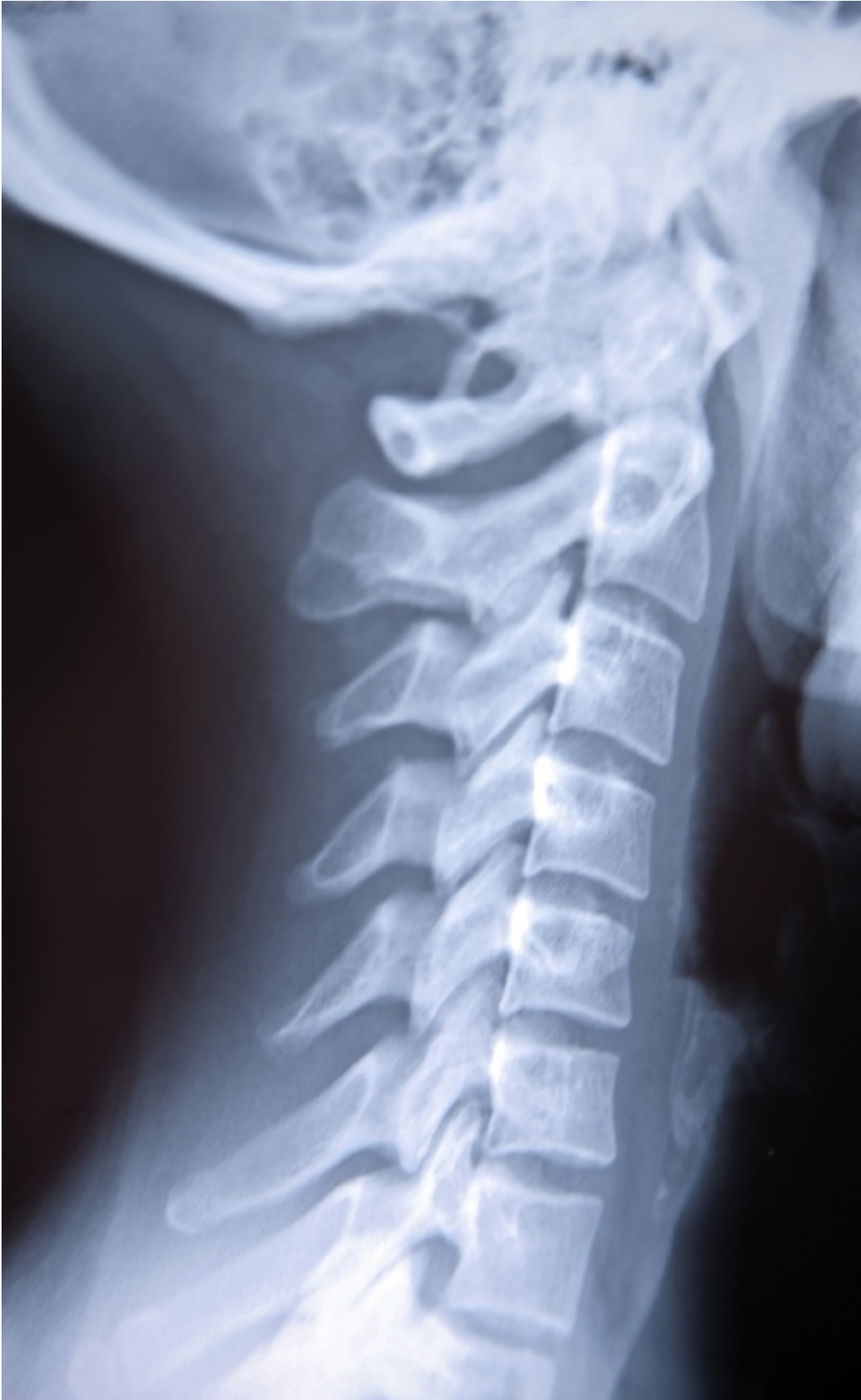Patient 8

18 y/o male experiencing severe neck pain after diving into the shallow end of a pool and hitting his head on the bottom



http://www.radiologyassistant.nl/data/bin/a5097978c7f0a2_flex7.jpg

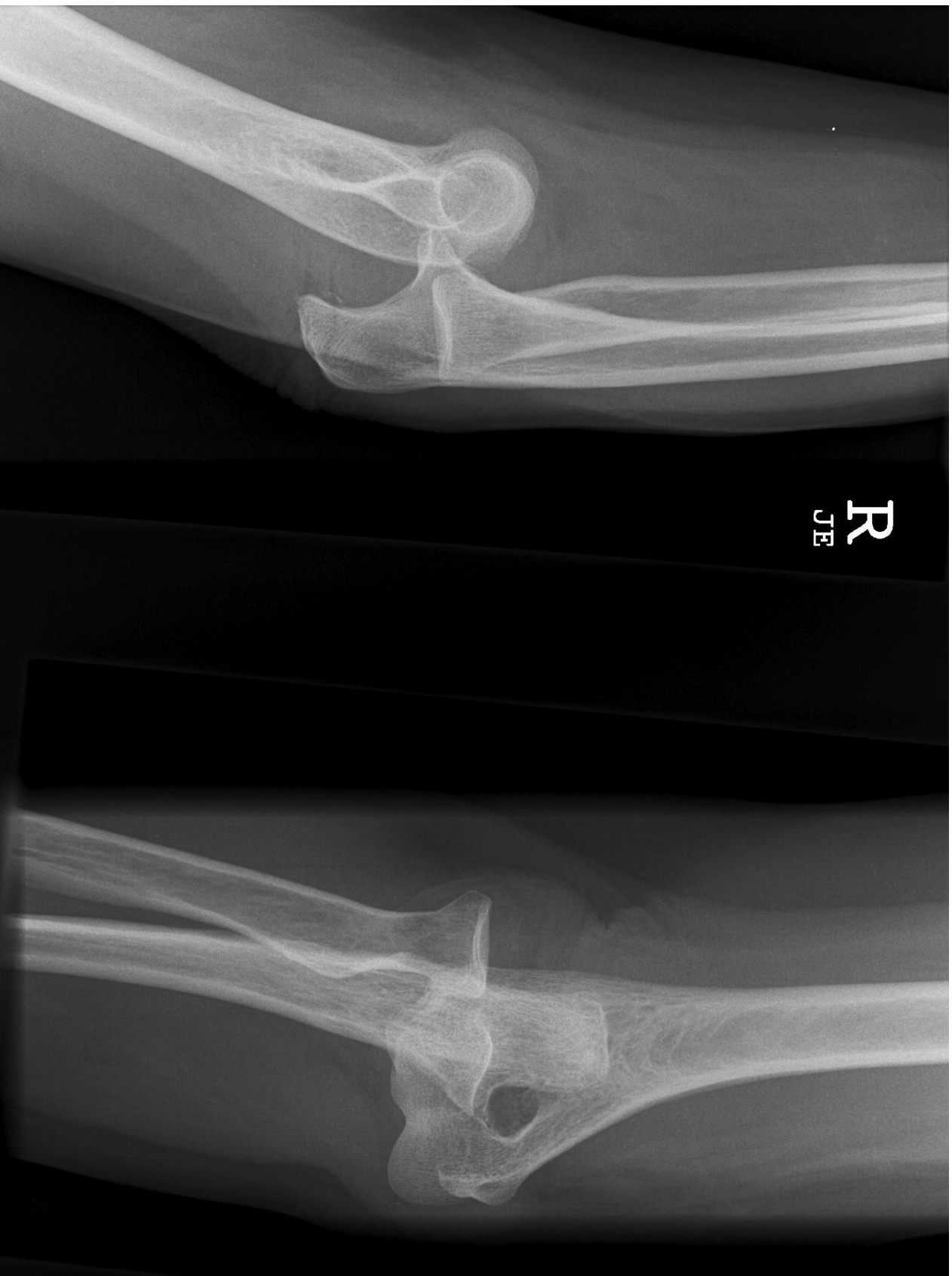NORMAL Neck



<http://www.glanvillechiro.com/wp-content/uploads/neck-x-ray.jpg>

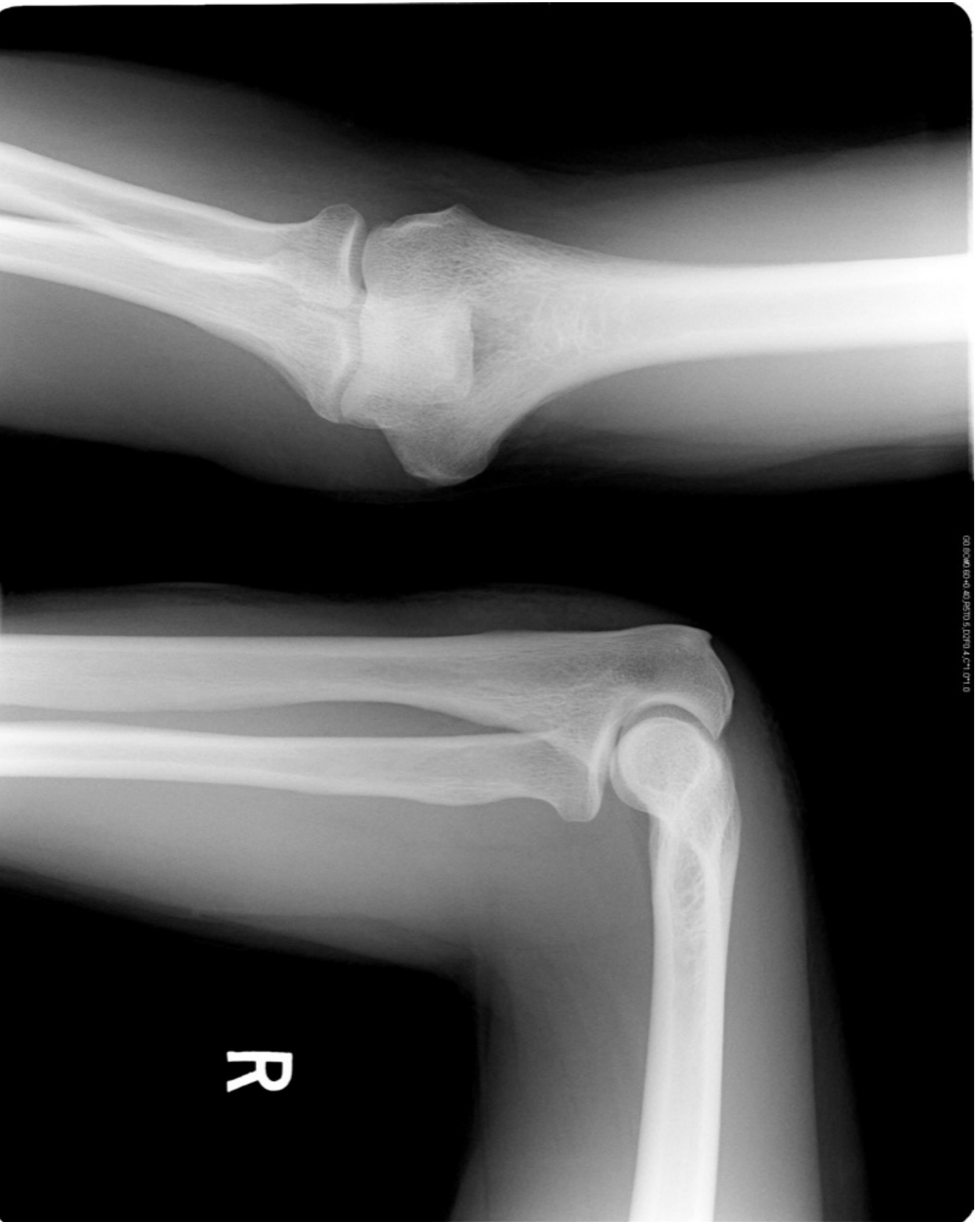Patient 9

17 y/o male experiencing elbow pain after being tackled and getting his arm caught at a "funny angle" during a football game.



NORMAL ELBOW

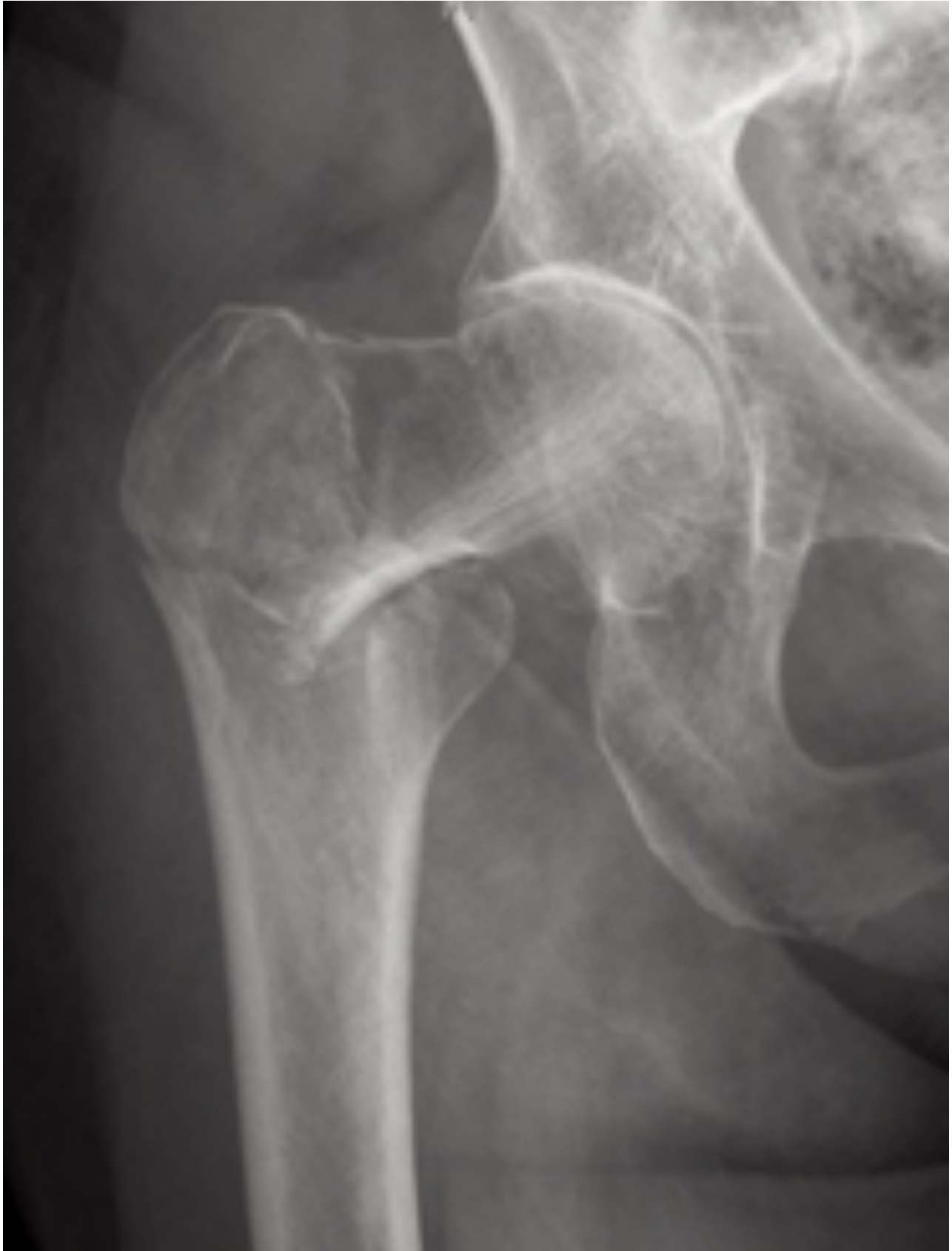001 00001 00 00 00 00 00 5 0000 4 001 001 0



<http://www.imageinterpretation.co.uk/images/elbow/NORMAL.jpg>

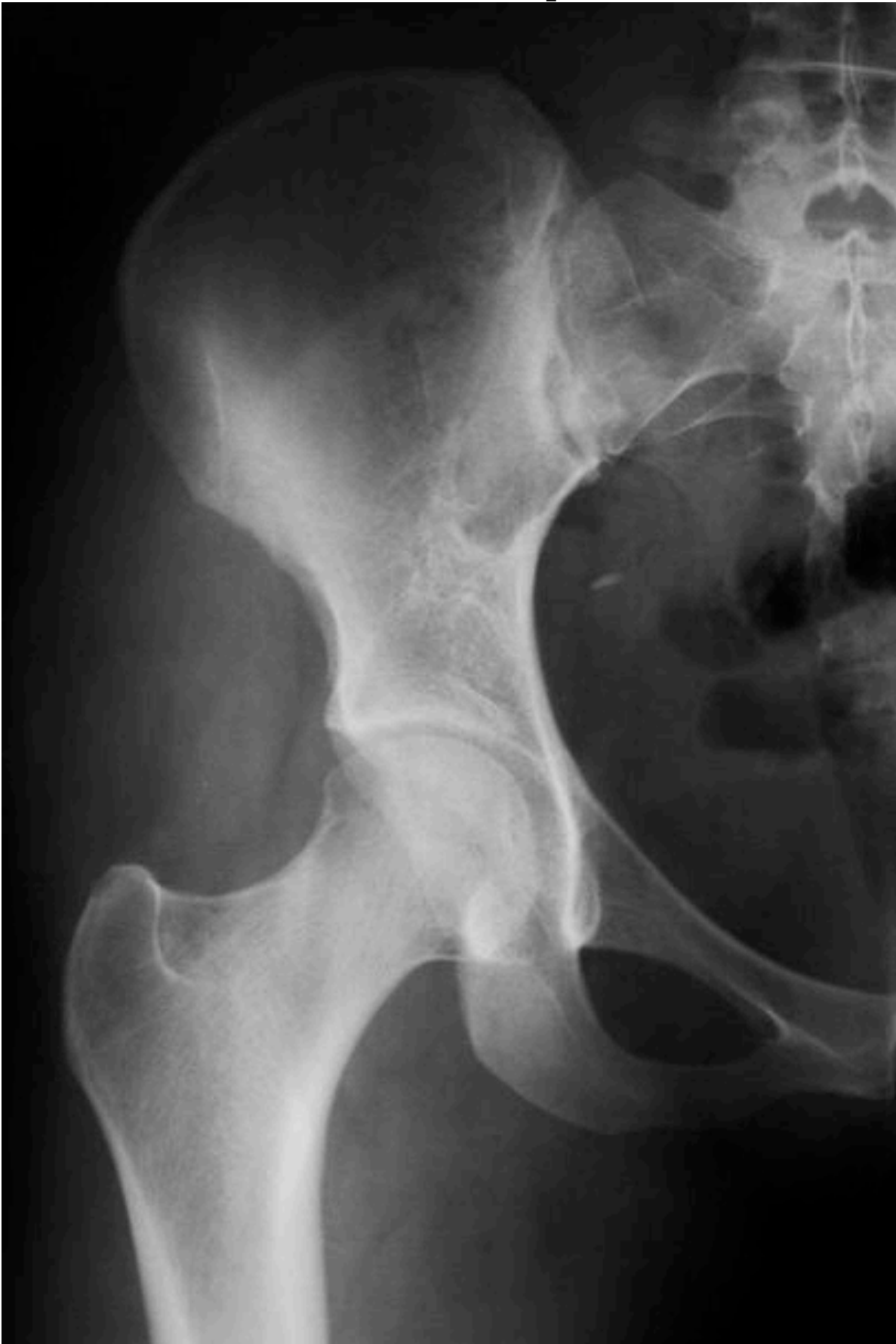Patient 10

72 y/o female experiencing hip pain following a misstep off of a curb



http://www.brighamandwomens.org/Medical_Professionals/education/publications/ppd/2012/July2012/Images/hip-fracture.jpg

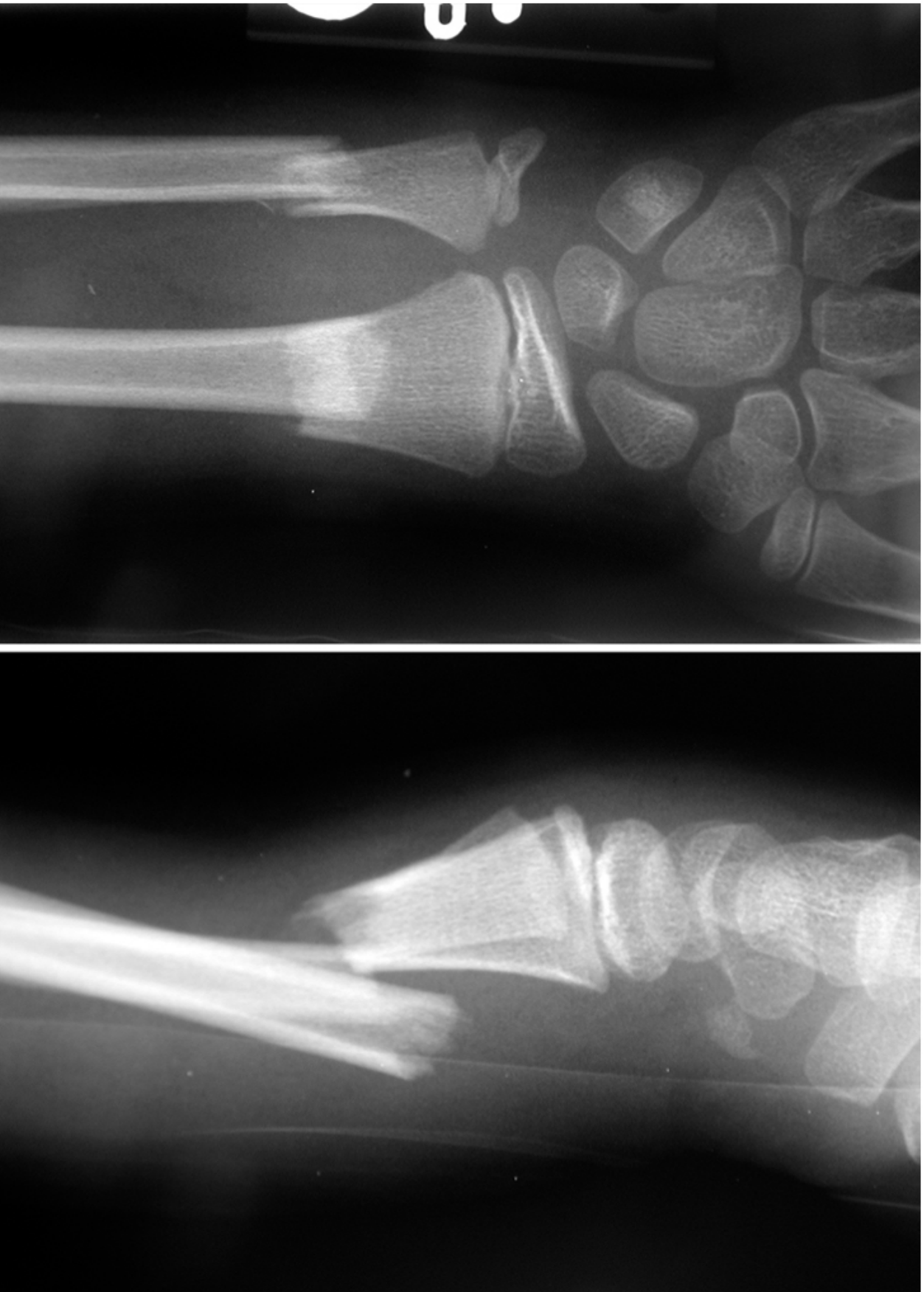NORMAL Hip



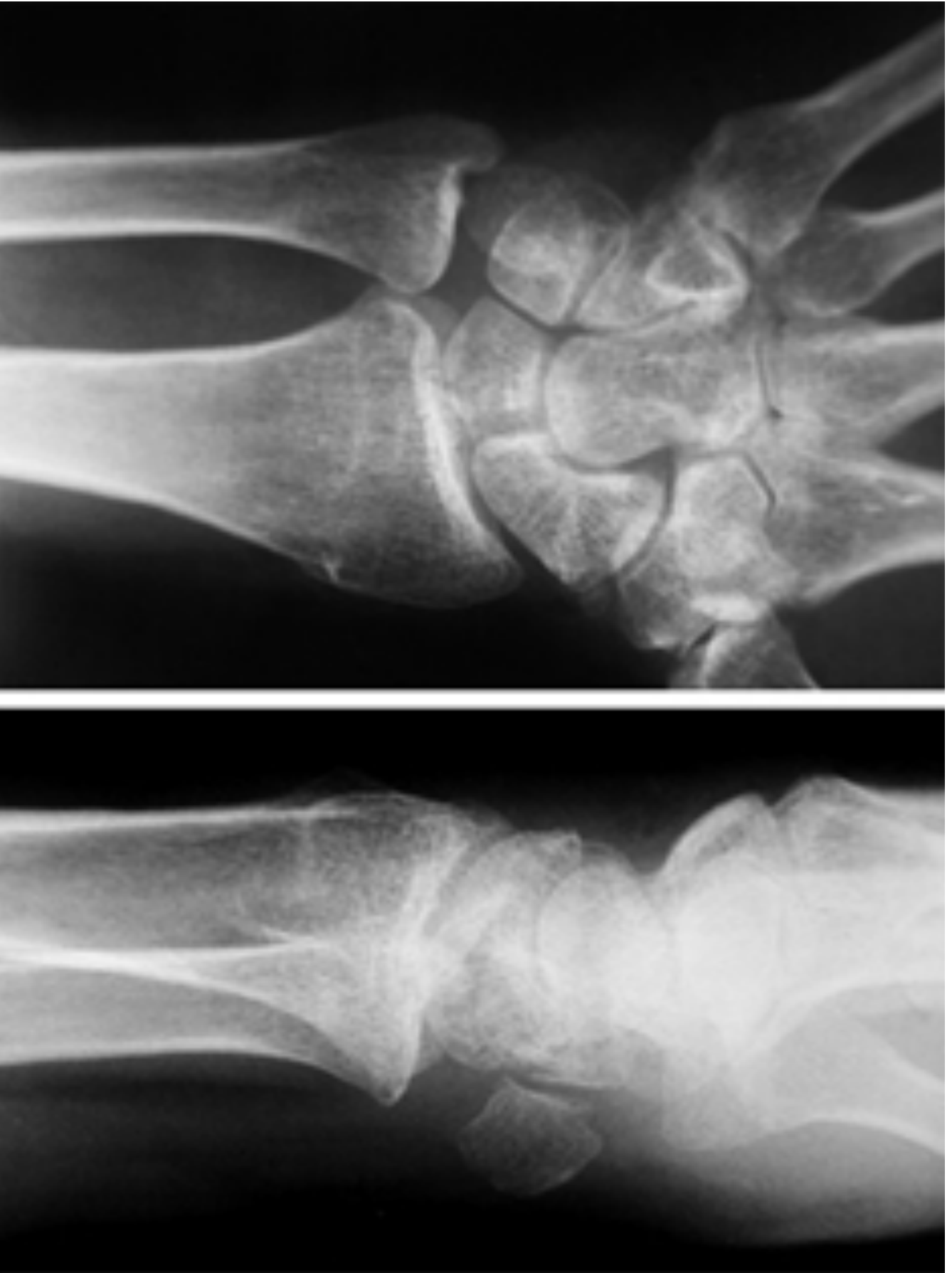<http://www.csosortho.com/images/hip-mis/mis-figure1a.jpg>

Patient 11

19 y/o male experiencing wrist pain after a failed dunk attempt; the patient fell to the ground landing on his hands.



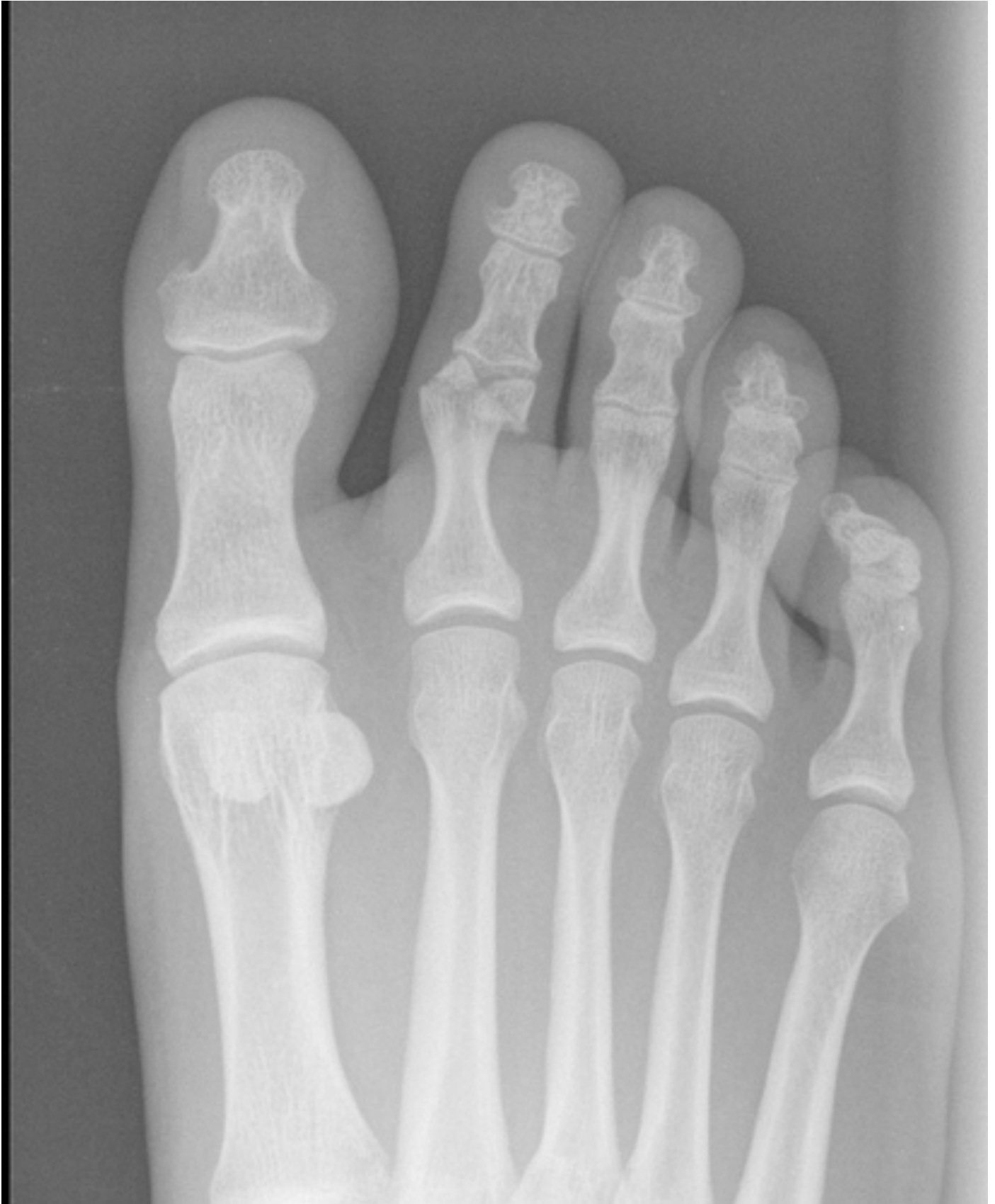NORMAL WRIST



http://memsi.uchc.edu/images/image_distal2.jpg

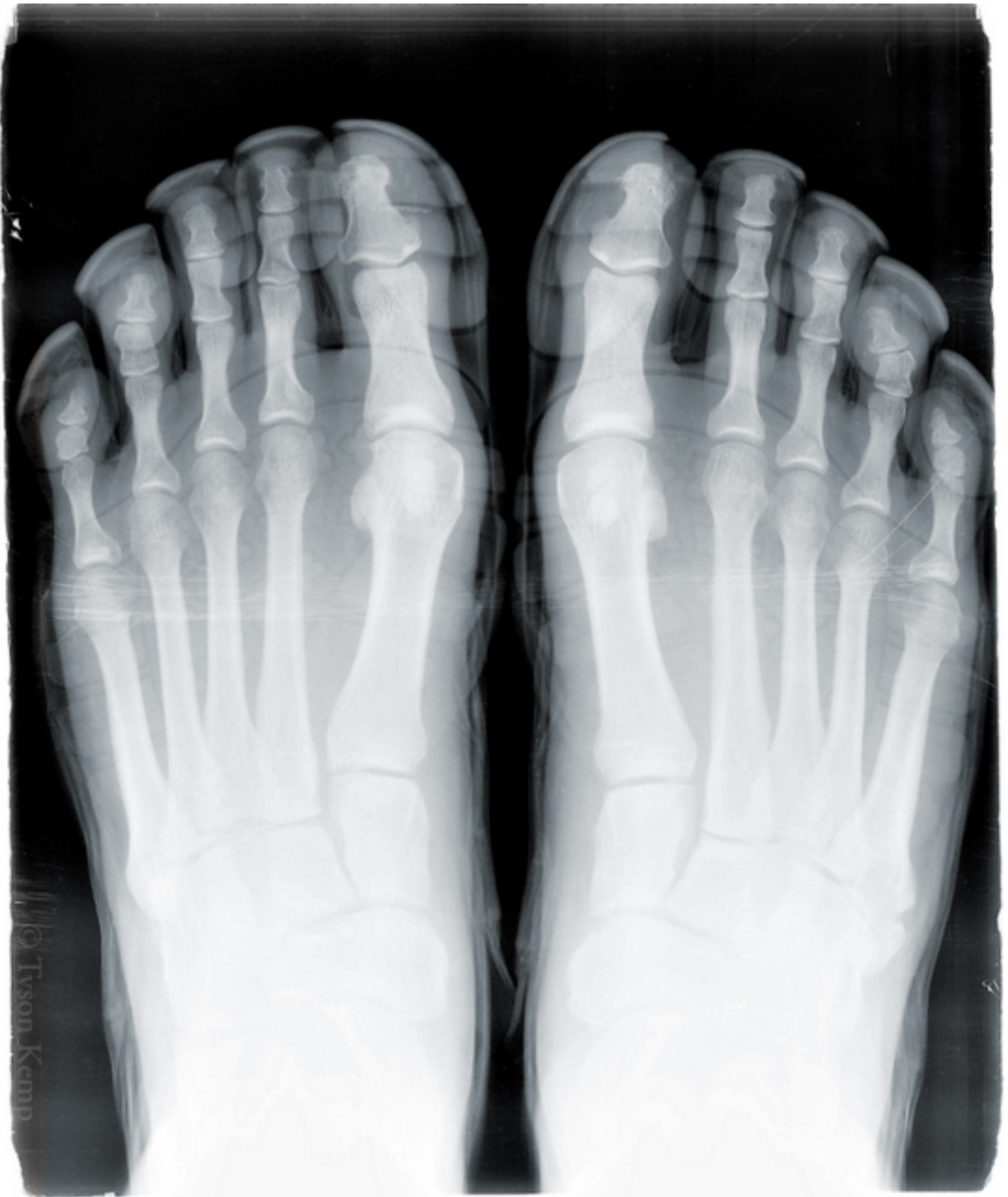Patient 12

41 y/o female who is experiencing foot pain after her horse stepped on her foot



http://farm5.static.flickr.com/4057/4412516621_bee20bfce.jpg

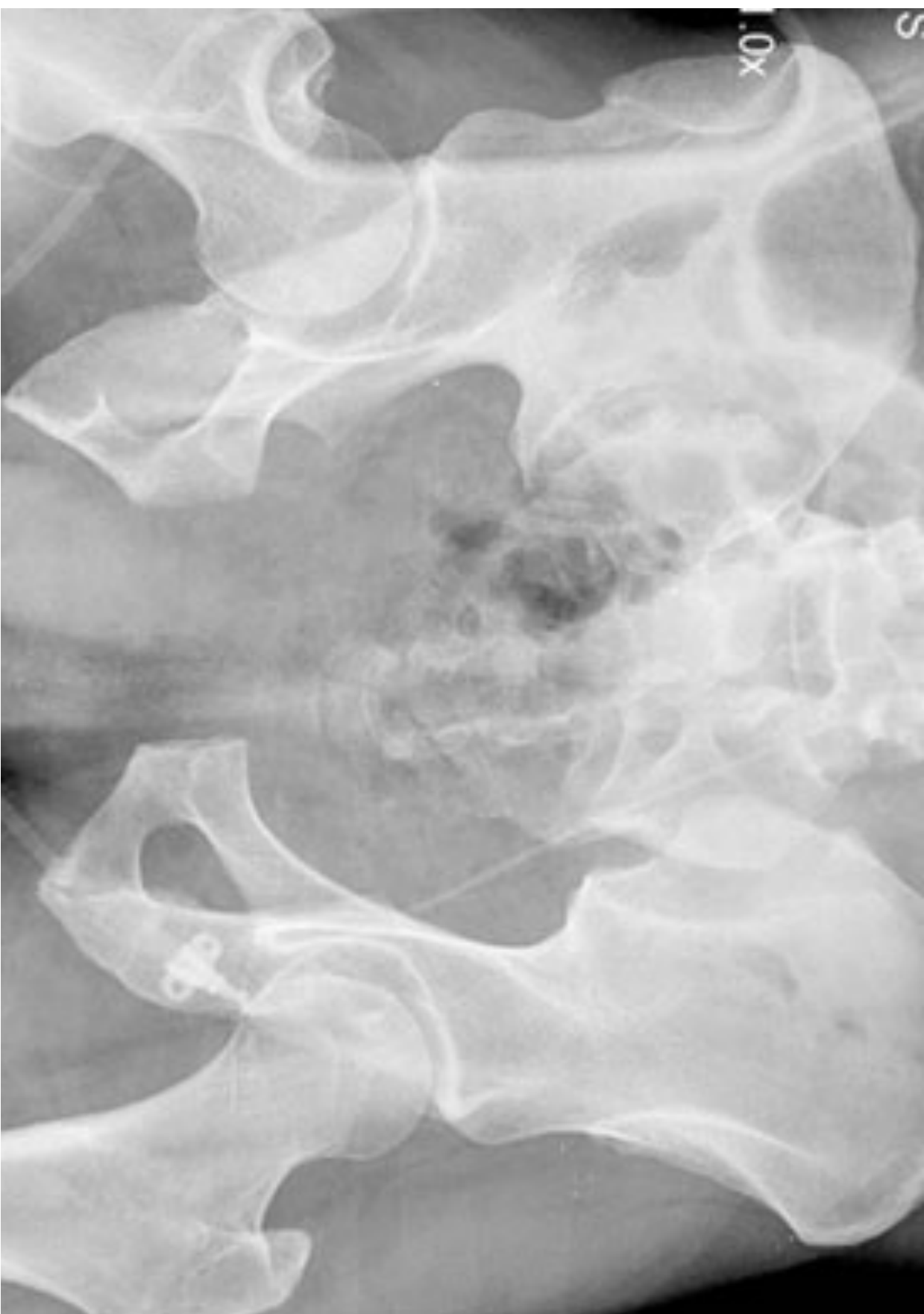NORMAL Foot



http://birthdayshoes.com/media/blogs/bdayshoes/2010_Photos/xray/xray.jpg?mtime=1275963540

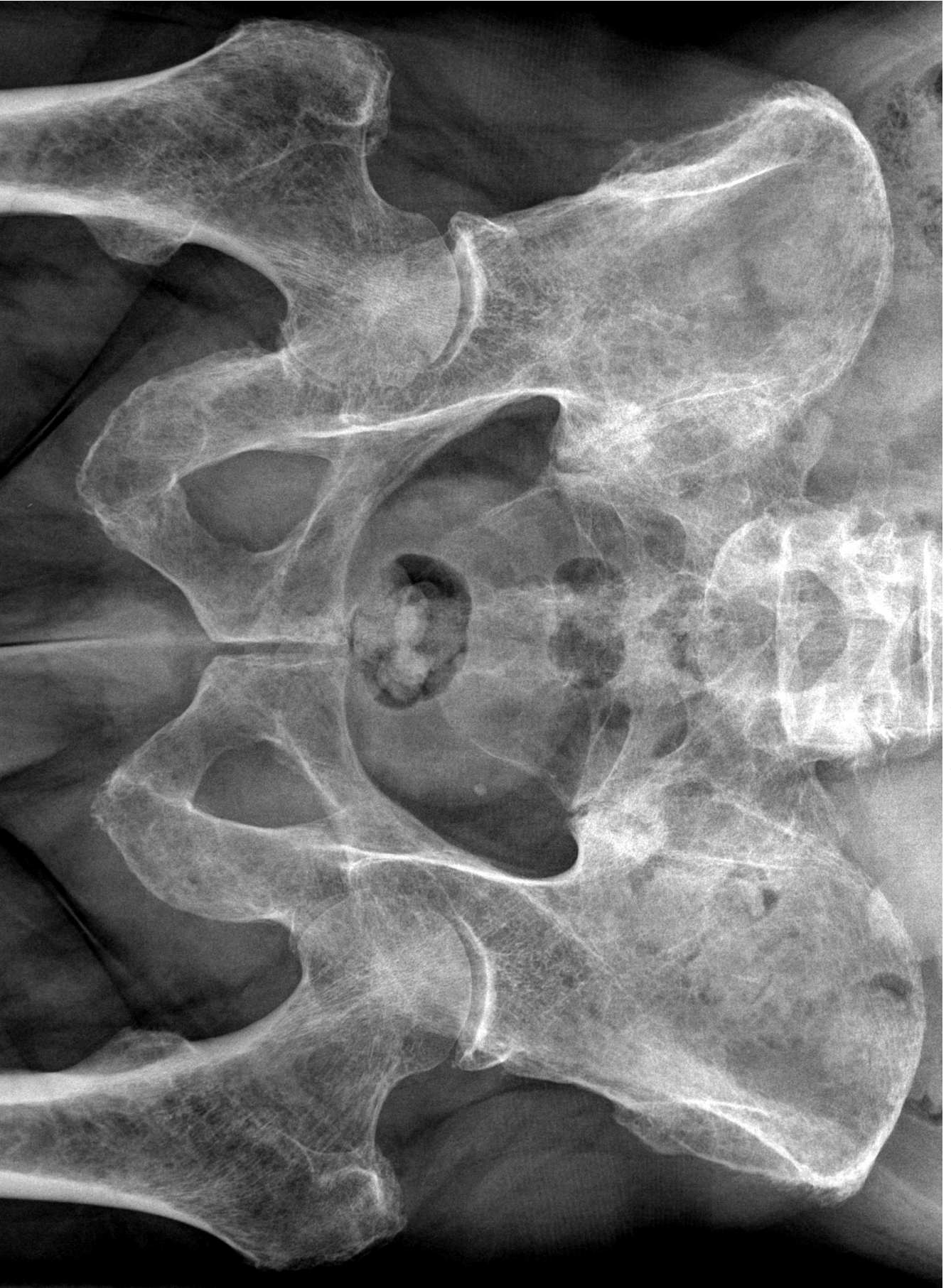Patient 13

44 y/o female in a severe car crash. Patient is currently comatose.



http://www.healio.com/~media/Curbside/Fracture_Management/Fig131.jpg

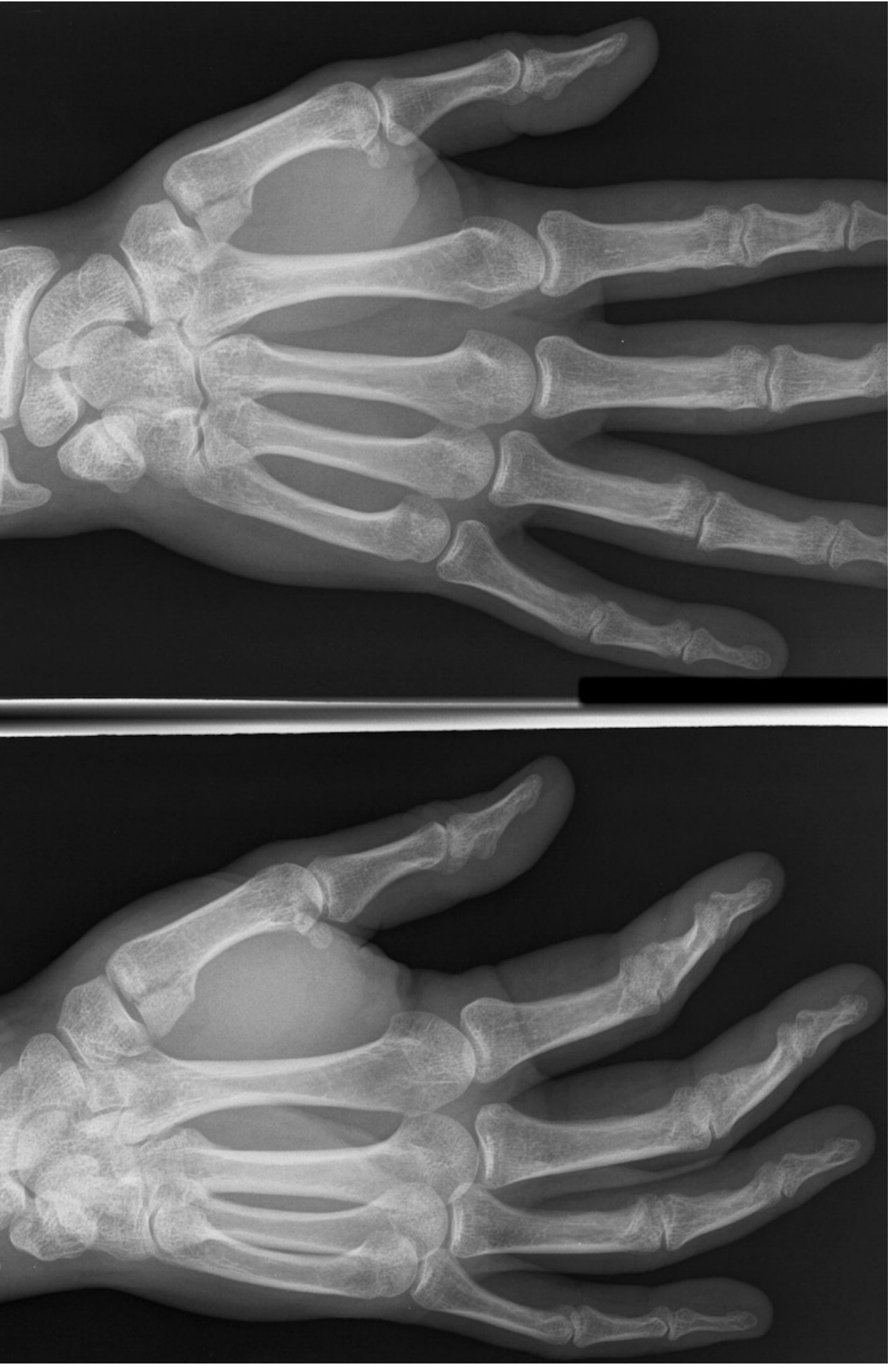NORMAL Pelvis



<http://images.radiopaedia.org/images/484706/497531e65d36faedfc889663558e1c3.jpg>

Patient 14

29 y/o male experiencing hand pain after attempting to break a board with hand during a martial arts exhibition.



NORMAL Hand



<http://images.wisegeek.com/hand-x-ray.jpg>