

Spinal Screening


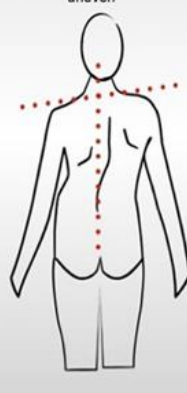




Parents,

Screenings for spine deformities are no longer being done in 7th & 8th grade PE classes. Parents need to be responsible to review these instructions and perform this simple examination annually on your child between the ages of 10-14.

















The purpose of spinal screening is to detect the signs of abnormal curves of the spine at their earliest stages so that the need for treatment can be determined. Scoliosis, a common spinal abnormality found in adolescents, is a sideways twisting of the spine. It is usually detected in children between 10 and 14 years of age. Kyphosis, sometimes called round back, is an exaggerated rounding of the upper back and is often confused with poor posture. Many cases of curvature of the spine are mild and require ongoing observation by a physician when they are first diagnosed. Others can worsen with time as the child grows and require active treatment such as bracing and surgery. Early treatment can prevent the development of a severe deformity, which can affect a person's appearance and health.

Home screening tests are simple and can be done with the child having no shirt on. For girls, a bra or a swimsuit that is low enough in back to show the lower back will be OK. Children, especially in the 10 to 15 year age range should be examined annually.

First look at your child from the back while he/she is standing with arms hanging to the side.

<p>Look for:</p> <ul style="list-style-type: none">•Shoulders are different heights – one shoulder blade is more prominent than the other•Head is not centered directly above the pelvis•Appearance of a raised, prominent hip•Rib cages are at different heights•Uneven waist•Changes in look or texture of skin overlying the spine (dimples, hairy patches, color changes)	<table border="0"><tr><td data-bbox="873 829 1079 934"><p>normal Torso is symmetrical, head and pelvis are in a straight line, shoulders are even</p></td><td data-bbox="1079 829 1289 934"><p>possible scoliosis Head is to one side of the natal cleft and not in a straight line with it; shoulders are uneven</p></td></tr><tr><td data-bbox="873 934 1079 1323"></td><td data-bbox="1079 934 1289 1323"></td></tr></table>	<p>normal Torso is symmetrical, head and pelvis are in a straight line, shoulders are even</p>	<p>possible scoliosis Head is to one side of the natal cleft and not in a straight line with it; shoulders are uneven</p>		
<p>normal Torso is symmetrical, head and pelvis are in a straight line, shoulders are even</p>	<p>possible scoliosis Head is to one side of the natal cleft and not in a straight line with it; shoulders are uneven</p>				
					

THEN: ask your child to bend forward, with arms hanging down and palms together (see picture below).

	<table border="0"><tr><td data-bbox="308 1417 568 1871"></td><td data-bbox="568 1417 909 1871"><table border="0"><tr><td data-bbox="568 1417 682 1871">Normal</td><td data-bbox="682 1417 909 1871">Abnormal</td></tr><tr><td></td><td></td></tr></table></td></tr></table>		<table border="0"><tr><td data-bbox="568 1417 682 1871">Normal</td><td data-bbox="682 1417 909 1871">Abnormal</td></tr><tr><td></td><td></td></tr></table>	Normal	Abnormal			<table border="1"><tr><td>Look for:</td></tr><tr><td>*Uneven contours – humps on one side</td></tr><tr><td>*Obvious curve in spine</td></tr><tr><td>*Exaggerated arches or roundness in upper back</td></tr></table>	Look for:	*Uneven contours – humps on one side	*Obvious curve in spine	*Exaggerated arches or roundness in upper back
	<table border="0"><tr><td data-bbox="568 1417 682 1871">Normal</td><td data-bbox="682 1417 909 1871">Abnormal</td></tr><tr><td></td><td></td></tr></table>	Normal	Abnormal									
Normal	Abnormal											
												
Look for:												
*Uneven contours – humps on one side												
*Obvious curve in spine												
*Exaggerated arches or roundness in upper back												

© Scoliosis Association (UK)

If you have questions or concerns contact your medical provider or school nurse